



International Journal of Pharmaceutics and Drug Analysis

Available at www.ijpda.com

ISSN: 2348:8948

Aging lung:acute exacerbation chronic obstructive pulmonary disease:case report

H. Jaasminerjiit Kaur^{1*}, Shashidharan Menon¹, Krupavaram.B¹, Kogila A/P Subramaniama¹, G.V.Nagaraju²¹ Centre of Excellence in Pharmaceutical Sciences, School of Pharmacy, KPJ Healthcare University College, Lot PT 17010, Persiaran Seriemas Utama, Kota Seriemas, 71800 Nilai, Negeri Sembilan, Malaysia² Faculty of Pharmaceutical Sciences, Jaipur National University, Rajasthan, India*Received: 08 May 2021 Revised: 20 June 2021 Accepted: 26 June 2021*

Abstract

A woman with aged 82 years old admitted to emergency hospital due to shortness of breath and chesty cough since last 3 days with underlying hypertension and chronic obstructive pulmonary disease. Patient's physical examination revealed tachypnea with respiratory rate of 28 beats per minute and series of spirometry examination was performed to diagnosed with acute exacerbation of COPD (GOLD A). Medication such as SABA and SAAC metered-dose inhaler, corticosteroid, and intravenous potassium and sodium infusion were given to control the patient's COPD condition as well as electrolyte imbalance issue. Follow up sessions and smoking cessation program also been arranged to improve and monitor the medical condition of the patient and to improve patient's quality of life. Pharmacist intervention on counselling and education in inhaler spacer together with the MDI device with proper storage and cleaning direction should be given to the patient and care givers.

Keywords: COPD, MDI, electrolyte imbalance.

This article is licensed under a Creative Commons Attribution-Non Commercial 4.0 International License.
Copyright © 2021 Author(s) retain the copyright of this article.



*Corresponding Author

H. Jaasminerjiit Kaur

Email: ucn.jaasminerjit@kpjuc.edu.myDOI: <https://doi.org/10.47957/ijpda.v9i2.474>

Produced and Published by

South Asian Academic Publications

Background

Chronic obstructive pulmonary disease (COPD) is characterized by persistent airflow limitation associated with a progressive chronic inflammatory response to the presence of noxious particles or gases in the airways and lungs. Worldwide COPD is expected to be the third prominent cause of death by year 2030 with estimated death count indicates a projection of 4 million people per year. The anatomical and physiological condition of respiratory system undergoes major reformation as a person age or in presence of genetic predisposition [1]. Occupation chemicals inhalation and tobacco smoking with underlying pneumonia or childhood respiratory infection could accelerate prognosis COPD.

Despite of physiological differences and underlying risk factor within different ethnic groups or genetic, commodities such as hypertension, dyslipidemia, obesity and chronic kidney disease may aggravate COPD and cost acute flare [2]. There is an increasing build of evidence where COPD as the manifestation of accelerated lung ageing and there is growing support of the close relationship between ageing and chronic inflammatory diseases [3]. The pharmacotherapy approaches still depends on inhaler, where cognitive impairment limits hand and mouth coordination noticed in elderly aged ≥ 75 years result in insufficient dosing and inadequate treatment [4]. This case report will concentrate on management of acute exacerbation of COPD in elderly patient.

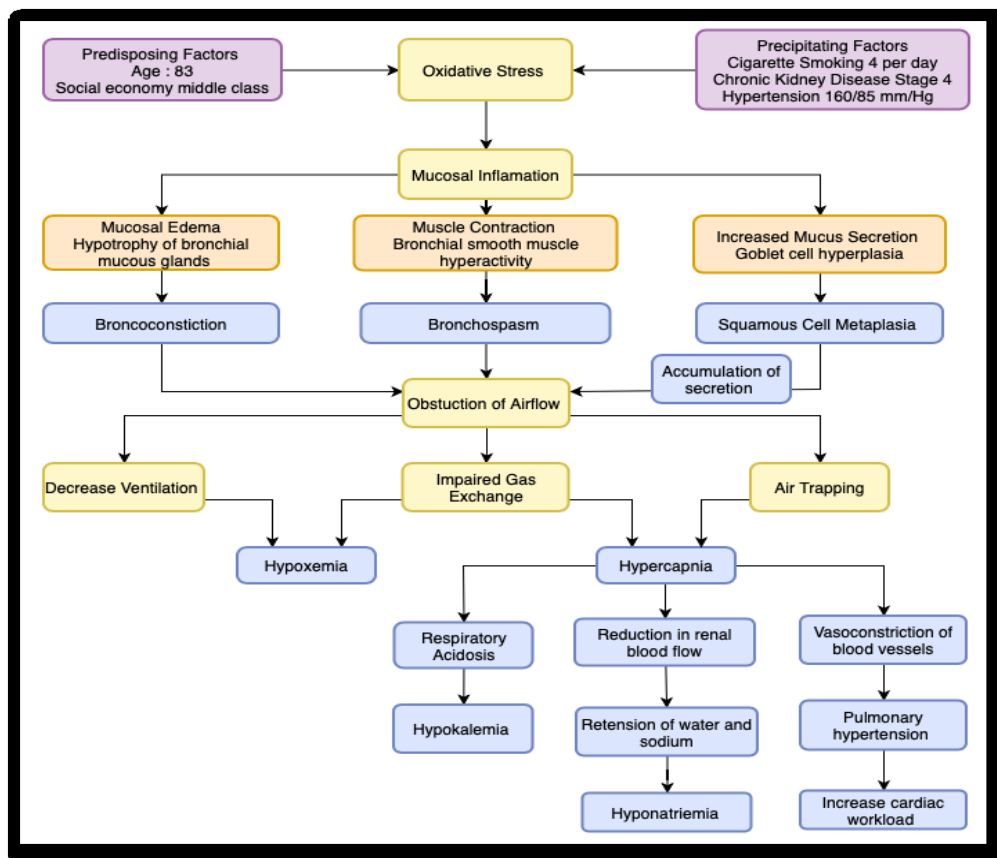


Fig 01: Pathogenesis of AECOD in present patient

Aging is a progressive degeneration of the tissues and cigarette smoke lead to over-activated oxidative metabolism, causing bronchial inflammation involving phagocytes, such as neutrophils and macrophages, adds an internal production of oxidants perpetuating the imbalances in favor of lung destruction. Squamous metaplasia, increased numbers of goblet cells, and increased size of bronchial submucosal glands results hypersecretion and abnormal mucociliary escalator. Precipitating problems cause gas exchange abnormalities, hypoxemia and hypercapnia where remodeling pulmonary arterioles result in persistent pulmonary hypertension and right ventricular hypertrophy. Respiratory muscle fatigue and alveolar hypoventilation can contribute to respiratory acidosis.

Case Presentation

A 82-year-old elderly women presented in the emergency department with shortness of breath and chesty cough with white thick phlegm for the past 3 days. She claimed having shortness of breath was accompanied with wheezing and it worsen at night prior to admission. She had underlying hypertension and COPD currently on Nuelin 250mg tablet, MDI Salbutamol when necessary and Spiriva Respimat inhaler 2.5mcg, two puff once daily where she stated

Spiriva Respimat inhaler finished 3 weeks ago. She had no family history of asthma or COPD, but she smokes 4 cigarettes per day. On examination she was with a blood pressure of 160/85 mm Hg, pulse rate 103 bpm and slightly tachypneic with respiratory rate of 28 breaths per minute. Lung examination showed rale bilaterally with no bronchi with 90% oxygen saturation. General examination was unremarkable.

Investigation

Table 01: Laboratory parameters

Criteria	Normal Range	Day 1	Day 3	Day 4	Criteria	Normal Range	Day 1
BP		160 /84	137 /59	136 /62	pH	7.35-7.45	7.46
Temp		37.1	36.9	37	PCO2	32-48 mm Hg	33.8
RR	12-18 b/min	28	20	28	pO2	83-108 mm Hg	106
WBC	4-11 x	8.3	-	7.9	O2 sat	90-95%	90

	109/ L						
Hb	11.5- 16.5 g/dL	11. 7	-	11. 2	Cl	96- 106 mmo l/L	85
Plate let	150- 400 x 109/ L	385	-	390	Ca	2.1- 2.6 mmo l/L	0.7 1
Urea	1.7- 8.3 mmo l/L	8.7	8.6	6.9	Mg	0.7- 1.3 mmo l/L	0.8 7
Na	135- 145 mmo l/L	124	131	137	Albu min	35- 50 g/L	23
K	3.5- 5.0 mmo l/L	2.6	3.4	3.5	T.Bilir ubin	<20 µmo l/L	8.5
SCr	64- 122 µmo l/L	117	102	84. 9	T.Prot ein	66- 87 g/L	55
ClCr	105- 150 mL/ min	21. 24	24. 36	29. 27	ALP	53- 141 u/L	73

The vital investigation revealed blood pressure fluctuation with 160/70 mmHg highest and 110/53 mmHg lowest. Mild tachycardia and tachypnoea were observed in emergency due to the acute exacerbation of COPD. In COPD patient, tachycardia in hypoxia arises as a result of stimulation of pulmonary stretch receptors during hyperventilation [5]. while tachypnoea is a normal response to hypoxemia [6]. Temperature and white blood cell were normal throughout the admission rules out infection. Arterial blood gas profile indicates patient was having acute metabolic alkalosis.

The input/output chart recorded a positive balance throughout admission period which commonly seen in CKD patient stage 4 where fluid overload had high risk for pulmonary edema followed by pulmonary hypertension. Patient had low hemoglobin level due to reduction in RBC production. Blood urea nitrogen and plasma creatinine increment and derangement of electrolyte (hyponatremia, hypokalemia and hypochloridemia and hypocalcemia) commonly seen in advance CKD patient. Otherwise all other lab value was in normal range.

Differential Diagnosis

She was having symptom's which include wheezing, coughing with purulent of sputum and speech in phrases with reduced effort tolerance. These symptoms' commonly overlaps with pneumonia, pulmonary edema secondary to heart failure and Asthma-COPD overlap syndrome. They perform a chest X-ray to view her lungs it was clear, so pneumonia was ruled out. The cardiovascular examination revealed dual rhythm no murmur, no cardiomegaly, no pedal oedema, no ECG changes, abdomen soft and not tender ruled out heart failure. Asthma-COPD overlap syndrome was kept in view because patient had noncompliance toward inhaler still impressed as acute exacerbation COPD.

Treatment

In emergency department, patient was given nasal prog oxygen therapy at rate of 3 L/min to improve oxygen saturation. Patient was prescribed Combivent nebulizer solution 2.5 mL (ipratropium bromide 500 µg, salbutamol 2.5 mg) 6 hourly to relieve the bronchoconstriction and elevate gas exchange efficiency. Patient was injected IV Hydrocortisone 200 mg stat and 100 mg three times a day for continuous 3 days to reduce inflammatory and suppresses immunology response.

Once patient stabilized, she was transferred to respiratory ward where 1 pint normal saline 0.9% w/v loaded with 1g potassium chloride was infused over 1 hour to correct the electrolyte based on result obtained. Patient was advised to continue her past medication Spiriva Respimat 2.5mcg/puff inhaler and MDI Ventolin 100 mcg/puff when necessary but tablet theophylline was with-hold. Patient hypertensive medication was continued as normal and patient was on CKD diet. Patient compliance and inhalation method was reviewed and requested for counselling.

Patient was responding well in the following days where 2 pints of intravenous drip normal saline 0.9% w/v with 0.5 gram of KCl in each pint given over 24 hours in day 2 and discontinued in day 3 while IV Hydrocortisone 100mg TDS was step down to oral Prednisolone 30 mg OD. There was an insertion continuous bladder drainage because the patient has difficulty in ambulate and dysuria due to progression of chronic kidney disease. In day 4 patient was switched from Spiriva Respimat to MDI Berodual N 2 puffs three times a day and nasal prog oxygen was discontinued due to stable saturation concentration achieved

In day 6 of admission patient was prescribed with tablet theophylline 250 mg twice a day, patient was given counselling by the pharmacist on inhalers and advised on smoking cessation program. Patient was prescribed Ravin enema one in the morning because she was having difficulty in bowel movement was advised to take fibrous food.

Discussion

According to clinical practice guideline in treating AECOPD by Ministry of Health (MOH) Malaysia suggest initial oxygen therapy to maintain adequate oxygenation $SpO_2 \geq 90\%$ without precipitating respiratory acidosis or worsening hypercapnia.(7) Controlled oxygen therapy should be given 1-2 liters per minute of oxygen via nasal prongs. Arterial blood gases should be checked 30-60 minutes later to ensure adequate oxygenation without CO_2 retention or acidosis.(8) (9) Patient had been prescribed with nasal prong oxygen therapy at 3 L/min to maintain sufficient oxygenation.

In severe exacerbations, nebulized SABA can be combined with a short- acting anticholinergic (SAAC), Combivent nebulizer solution 2.5 mL (ipratropium bromide 500 μ g, salbutamol 2.5 mg) 6 hourly or Duovent nebuliser solution 4 mL (ipratropium bromide 500 μ g, fenoterol 1.25 mg) 6 hourly. (7) Intravenous methylxanthines can be considered in severe exacerbations if there is inadequate response to inhaled SABA and SAAC. Patients already on maintenance theophylline treatment should not be given a loading dose. Global Initiative for Chronic Obstructive Lung Disease (GOLD) recommended short-acting beta-adrenergic agonist (SABA) or short-acting anticholinergic (SAAC) or combination of both when necessary for patients with COPD stage 1 or stage A [10].

Theophylline clearance decreased approximately 15-30% in the elderly group compared with the young group, probably reflecting decreases in metabolic elimination of the theophylline by cytochrome enzymes including CYP 1A2, CYP 2E1 and CYP 3A4. Smoking affects the clearance of theophylline by inducing theophylline metabolism in the liver as demonstrated by a study that smoking accelerates theophylline clearance by approximately 57% in the young and approximately 47% in the elderly [7]. Since patient is elderly, active smoker, and had been diagnosed with Stage 4 chronic kidney failure could impact theophylline clearance and hypokalemia was also notice in this patient.

Systemic corticosteroids improve lung function over the first 72 hours, shorten hospital stay and reduce treatment failure over the subsequent 30 days [11]. A dose of 30-40 mg of oral prednisolone daily for 7-14 days appears to be safe and effective. Since the lung function had been improved on third day of admission with patient's oxygen saturation ranged from 96% to 98%, doctor switched the corticosteroid injection into tablet form which should be continuously taken by patient after discharged for another 10 days [12].

Antibiotics are beneficial during AECOPD but have no proven benefit to prevent exacerbations. Patient had 1 out of 3 cardinal symptoms, increased dyspnea with thick white sputum secretion. However, the initiation of antibiotic is still required since the patient required non-invasive ventilation as well as Combivent nebulizer which possess risks of nosocomial infection [13]. The preferred antibiotic for simple COPD recommended by clinical practice guideline (CPG) is Azithromycin 500 mg once daily for 3 days.

According to clinical practice guideline published by European Renal Association (ERA), profound hyponatremia is defined as a biochemical finding of a serum sodium concentration < 125 mmol/L as measured by ion specific electrode. Patient serum sodium concentration was 124 mmol/L on the admission day [14]. Since 0.9% sodium chloride (normal saline) containing 154 mmol/L of Na^+ ions and 272.2 mmol/L of Na^+ ions are required by patient, approximately 2 liters of normal saline should be given as intravenous infusion over 24 hours to increase the serum sodium concentration by 8 mmol/L to 132 mmol/L. The intravenous infusion of normal saline should be repeated for another 24 hours to increase the serum sodium concentration to 140 mmol/L. A higher concentration of sodium chloride solution should be used to reduce the volume of infusion because this patient having CKD.

Hypokalaemia is defined as a serum potassium level of less than 3.5 mmol/L. Moderate hypokalaemia is a level of 2.6 – 2.9mmol/L. Since 90% of potassium is intracellular, therefore a small drop in serum (extracellular) potassium can represent a much larger drop in terms of the total body potassium content, hence, it is always necessary to consider the clinical state of the patient and any diseases that may be causing potassium to shift from the intracellular to extracellular space [15]. An ampoule containing 1 gram of potassium chloride solution in 10 mL (10%) provide 13.4 mmol of

K⁺ ions. Hence, a total of 5 ampoules of potassium chloride solution (13.4 mmol/L) is required to provide sufficient potassium replacement.

According to Clinical Practice Guideline (CPG) on Management of Hypertension, the treatment systolic blood pressure target for very elderly adults (> 80 years old) is less than 150 mmHg and treatment should only be initiated in very elderly adults when systolic blood pressure is more than 160 mmHg (Hypertension Guideline Working Group, 2018). Smoking cessation is the single most effective and cost-effective intervention in most people to reduce the risk of developing COPD and stop its progression. All smokers should be offered smoking cessation interventions [16]. Patient anemic condition was taken lightly its best to initiate folic acid 400 mcg tablet to be taken once daily and vitamin B12, 500 mcg tablet to be taken once daily.

Outcome and Follow-Up

Patient was referred for smoking cessation program and contrast-enhanced computed tomography (CECT) thorax after 3 weeks with CT guided biopsy to examine the images of lung nodule for malignancy. Patient was discharged with MDI Berodual 2 puffs TDS, MDI Salbutamol 2 puffs PRN, oral Prednisolone Tablet 30 mg OD and Theophylline Tablet 250 mg BD. Patient will be referred to nephrologist follow-up on end stage renal failure workout.

Conclusion

COPD is a major public health problem that affects a significant proportion of the elderly population. While the prevalence and morbidity of COPD in the elderly are high, it is often undiagnosed and thus undertreated. Moreover, the elderly population is considered as one of the most challenging population in managing COPD due to the comorbidities and polypharmacy of medications that took by this population of patient. Since several disorders present in this patient such as hyponatremia, hypokalemia, renal impairment and COPD, the selection of medication and treatment strategy should be wisely determined. Hence, appropriate intervention should be carried out by the healthcare professionals in order to optimize the treatment strategies for patient and improve patient's quality of life.

Conflict of Interest

Authors do not have any conflicts of interest.

Author Contributions

All Authors Contributed Equally.

Abbreviations

CECT: Contrast-enhanced computed tomography
CKD: Chronic kidney disease
COPD: Chronic obstructive pulmonary disease
CPG: Clinical Practice Guideline
CT: computed tomography
ECG: Electrocardiogram
ERA: European Renal Association
MDI: Metered dose inhaler
OD: Once daily
PRN: Pro re nata
SAAC: Short-acting anticholinergic
SABA: Short-acting beta-adrenergic agonist
TDS: ter die sumendum

Reference

1. Conti V, Corbi G, Manzo V, Pelaia G, Filippelli A, Vatrella A. Sirtuin 1 and aging theory for chronic obstructive pulmonary disease. *Analytical Cellular Pathology*. 2015;2015.
2. Chetty U, McLean G, Morrison D, Agur K, Guthrie B, Mercer SW. Chronic obstructive pulmonary disease and comorbidities: a large cross-sectional study in primary care. *British Journal of General Practice*. 2017;67(658):e321-e8.
3. Jayadev A, Gill S. COPD in the elderly: The ageing lung. *GM*; 2017.
4. Bourbeau J, Bartlett S. Patient adherence in COPD. *Thorax*. 2008;63(9):831-8.
5. Korner P, Edwards A. THE IMMEDIATE-EFFECTS OF ACUTE HYPOXIA ON THE HEART RATE, ARTERIAL PRESSURE, CARDIAC OUTPUT AND VENTILATION OF THE UNANÆSTHETIZED RABBIT. *Quarterly Journal of Experimental Physiology and Cognate Medical Sciences: Translation and Integration*. 1960;45(2):113-22.
6. Goldman L, Schafer AI. *Goldman's Cecil medicine* [Internet]. Philadelphia: Elsevier Health Sciences; 2012.
7. Lim TK, Chee CB, Chow P, Chua G, Eng SK, Goh SK, et al. Ministry of Health clinical practice guidelines: Chronic obstructive pulmonary disease. *Singapore Med J*. 2018;59(2):76-86.

8. Rabe KF, Hurd S, Anzueto A, Barnes PJ, Buist SA, Calverley P, et al. Global strategy for the diagnosis, management, and prevention of chronic obstructive pulmonary disease: GOLD executive summary. *American journal of respiratory and critical care medicine.* 2007;176(6):532-55.
9. Kim V, Benditt JO, Wise RA, Sharafkhaneh A. Oxygen therapy in chronic obstructive pulmonary disease. *Proceedings of the American Thoracic Society.* 2008;5(4):513-8.
10. Roche N, Criner G, Vogelmeier C. GOLD Reports on Chronic Obstructive Pulmonary Disease (COPD): Evolutions, Revolutions and Controversies. 2019.
11. Davies L, Angus R, Calverley P. Oral corticosteroids in patients admitted to hospital with exacerbations of chronic obstructive pulmonary disease: a prospective randomised controlled trial. *The Lancet.* 1999;354(9177):456-60.
12. Schols A, Wesseling G, Kester A, De Vries G, Mostert R, Slangen J, et al. Dose dependent increased mortality risk in COPD patients treated with oral glucocorticoids. *European Respiratory Journal.* 2001;17(3):337-42.
13. Nouira S, Marghli S, Belghith M, Besbes L, Elatrous S, Abroug F. Once daily oral ofloxacin in chronic obstructive pulmonary disease exacerbation requiring mechanical ventilation: a randomised placebo-controlled trial. *The Lancet.* 2001;358(9298):2020-5.
14. Spasovski G, Vanholder R, Allolio B, Annane D, Ball S, Bichet D, et al. Clinical practice guideline on diagnosis and treatment of hyponatraemia. *Nephrology Dialysis Transplantation.* 2014;29(suppl_2):i1-i39.
15. Kardalas E, Paschou SA, Anagnostis P, Muscogiuri G, Siasos G, Vryonidou A. Hypokalemia: a clinical update. *Endocrine connections.* 2018;7(4):R135-R46.
16. Preventive U. Services Task Force. Counseling and interventions to prevent tobacco use and tobacco-caused disease in adults and pregnant women: US Preventive Services Task Force reaffirmation recommendation statement. *Ann Intern Med.* 2009;150(8):551-5.